

Case Report,

Canalicualr adenoma in buccal space area : a case report

Abdulaziz Alwakeel¹ , Asma Shiekh Musa²

¹Oral pathologist, Oral Medicine and Pathology department , Tabuk Dental Center, Tabuk, Saudia Arabia

²Histopathologist, Laboratory and Blood Bank, Maternity and children Hospital, Tabuk, Saudia Arabia

Abstract:

Introduction: Canalicular adenoma (CA) is considered a rare benign salivary gland neoplasm, although it was suggested that this lesion has a terminal duct origin. The most common location of this lesion is the upper lip which accounted for 80% of cases, followed by buccal mucosa and palatal area, it presented as a solitary lesion in middle age more in female patients.

Case presentation: 75 years old, male, medically fit referred to the oral medicine and pathology clinic because he complaint of right cheek swelling for several years associated with discomfort but no associated pain or increase in the size of the lesion that presented in his cheek, the patient clinical examination revealed hard well-demarcated lesion in buccal area extended up to the zygomatic bone area, lesion can be palpable by using bi digest technique, CT x-ray was done for patient and shows two cystic lesions in right buccal space area, excisional biopsy done and histopathological evaluation revealed the diagnosis was Canalicular adenoma

Conclusion: Canalicular adenoma is a benign salivary gland neoplasm that can be presented as solitary or multiple but solitary type more common, usually effect the upper lip and more in female patients with middle age, In our case the lesion presented in buccal mucosa area in male patient above 70 years old, clinical and histopathological evaluation is important to reach the diagnosis, clinical follow up is recommended in such lesion because there is a chance for recurrences

Key word: salivary gland, tumor, neoplasm, canalicular adenoma.

Introduction:

Canalicular adenoma (CA) is considered a rare benign salivary gland neoplasm, although it was suggested that this lesion has a terminal duct origin(1,2)

The most common location of this lesion is the upper lip which accounted for 80% of cases, followed by the buccal mucosa and palatal area (3, 4).

The tumor appears clinically as a solitary or multifocal, but the solitary type is more common, the clinical feature of this lesion also presents as a painless lesion with some mobility, slowly growing, firm, or slightly fluctuant on palpation (5, 6).

They have a similar histologic appearance to the main tumor. Some authors have referred to these as “adenomatous” growths, highlighting the lack of destructive or infiltrative growth (7)

The histologic differential diagnosis includes several types of benign salivary gland neoplasms such as basal cell adenoma and pleomorphic adenoma, reticulated myoepithelioma, and malignant type of salivary gland neoplasms such as pleomorphic adenocarcinoma, adenoid cystic carcinoma (ACC), ductal adenoma (8, 9). However, CanAd represents 1 % of all tumors presented in salivary glands (10).

The aim of this case report the canalicular adenoma was reported in the buccal space area of a male patient which is less commonly seen in that area

Case report:

75 years old, male, medically fit referred to the oral medicine and pathology clinic because he complained of right cheek swelling for several years associated with discomfort but no associated pain or increase in size lesion presented in his

cheek several years ago and he feeling discomfort but with no pain or increasing in size, patient clinical examination reveled hard well-demarcated lesion in buccal mucosa area extended up to the zygomatic bone area, the lesion can be palpable by using bi digest technique, CT with contrast was done for patient and shows two cystic lesions in right buccal space area with no significant of edema, inflammation, and bone invasion as shown

in figure number (1,2), excisional biopsy done and macroscopic evaluation shows polypoid lesion attached to fibrous tissue with papillary surface measuring 1.5x 1.2 x 0.9cm after dissection. Microscopic examination shows single strands of epithelium making bilayer, the epithelial cells mainly cuboidal and columnar cells area of vascularization seen. Intraluminal squamous balls or morules. As shown in figures (3,4,5,6)

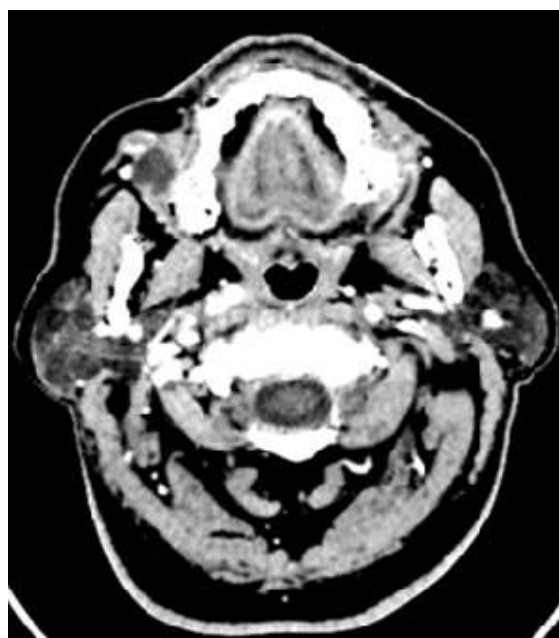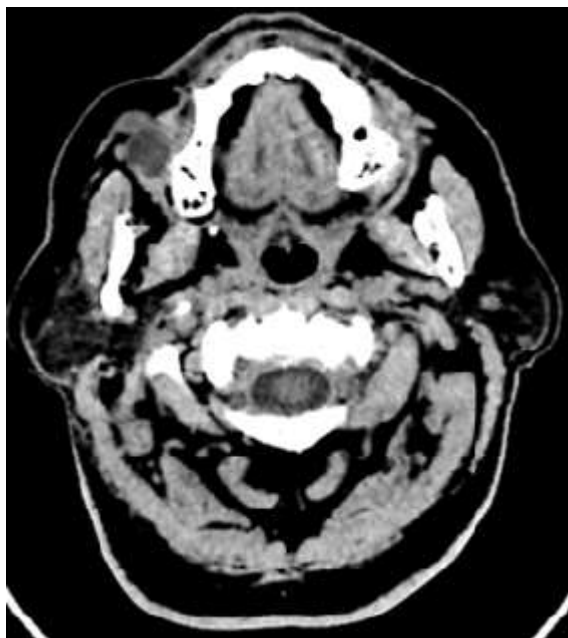


Figure (1,2). CT with contrast shows two cystic lesions in the right buccal mucosa measuring mm with no significant edema and inflammation or bone invasion.

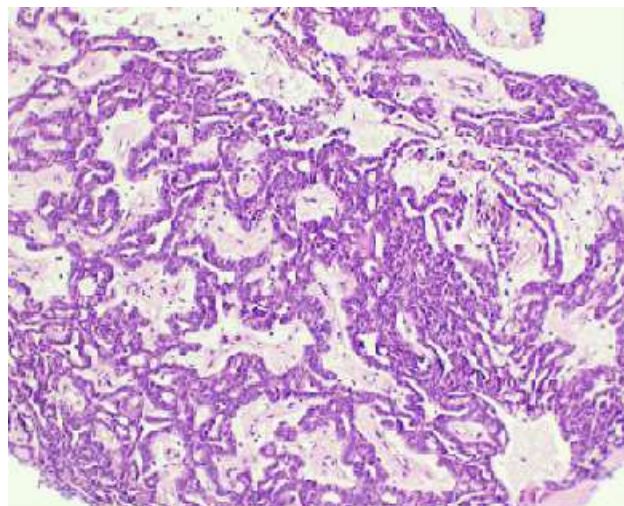
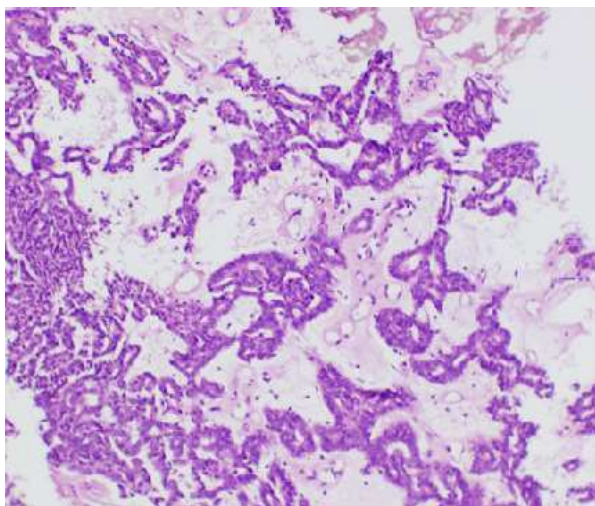


Figure 3 :This section shows a tubular growth pattern with multiple areas of club-ended cords and small lumina, loose fibrous stroma in between

Figure 4:This section shows cords made in parallel rows and some joining in multiple areas.

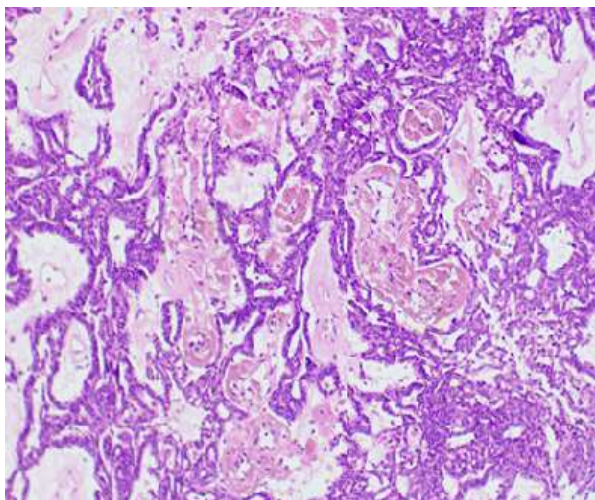


Figure 5: Cyst formation with vascular fibro-collagenous background

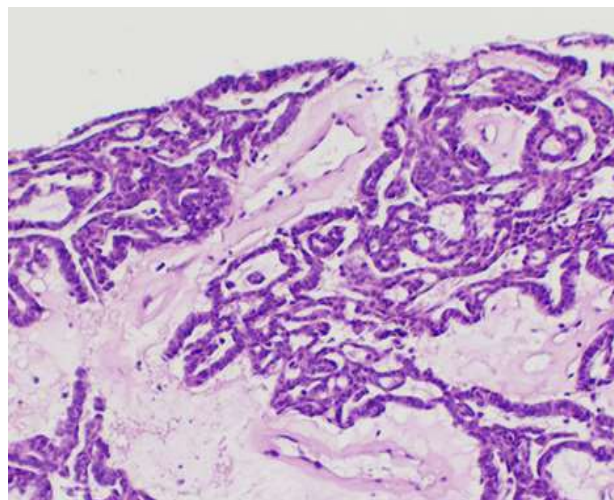


Figure 6: This section shows Intraluminal squamous balls or islands noted (arrow)

Discussion:

Historically canalicular adenoma was considered a branch of basal cell adenoma which was recognized as a separate disease for the first time in the 1991 WHO classification (11).

Some studies have reported that canalicular adenoma is almost 7–12% of all benign salivary tumors, making it the 3rd or 4th most common benign epithelial salivary gland tumor. CA is more common in female with female to male ratio of 1.7:1. Middle age or older patient has a high affected rate, occurring almost exclusively in patients over 50 years of age, with a range of 33–91 years. The lesion presented an asymptomatic, most present with a painless, un-ulcerated mass with slowly growing and an average duration of about 3 years. (12,13)

The majority of these lesions occur in the upper lip, the rest occur in the buccal mucosa and the hard palate, and at other sites. The clinical differential diagnosis includes salivary gland, soft tissue and vascular lesion like: a mucocele, thrombosed vessel and lipoma. (12) In This case the tumor was identified in the buccal space area in a male patient, the clinical and radiographic differential diagnosis includes: soft tissue neoplasms like lipoma and fibroma and salivary gland neoplasm like pleomorphic adenoma

The tumor is surrounded by a thin fibrous capsule tissue with lobular architecture. The capsule measuring (1 cm) in size rarely larger than 2 cm, and may be discontinuous. Multifocal tumors are observed infrequently (about 9 %of all cases) when combining the present series with those from the literature. Further, there can be a range from 2 to 22 separate tumors (14, 15). In the

presented case the lesion in macroscopic evaluation has a polypoid feature attached to fibrous tissue with a papillary surface after dissection with a tumor size of almost 1cm

Cyst formation can be seen in majority of cases, extravasated erythrocytes, hemosiderin, lipofuscin-laden macrophages or foamy histiocytes may presented in CA (12).

Squamous balls, a fairly specific feature of CA, it is usually present in the cystic lumen but always connect to the epithelium with serial sections (possibly the tips of papillae) (12).

The joining parallel rows of epithelial cells is a characteristic feature of CA. The lesional cells are columnar with a low rate of pleomorphism. The nuclear chromatin is delicate, stippled to focally hyperchromatic. The stroma of CA is usually edematous, hypocellular, fibrillar to myxoid associated with collagen deposition (sclerosis) in most cases. (12). Similar to the presented case, strand and cords made parallel rows and shows some joining in multiple areas. The fibro-collagenous background can be noted

The absence of chondroid or cartilaginous matrix material in this tumor can help to exclude some of salivary gland neoplasm such as pleomorphic adenoma. (12)

Complete surgical removal of this lesion is the treatment of choice. Follow-up of the patients recommended for this type of lesion, especially in multinodular lesion type. (12)

One study review shows the canalicular adenoma has some recurrence rate of around 3% of cases(13).

Conclusions:

Canalicular adenoma is a benign salivary gland neoplasm that can be presented as solitary or multiple but solitary type more common, usually effect the upper lip and more in female patients with middle age, In our case the lesion presented in buccal mucosa area in male patient above 70 years old, clinical and histopathological evaluation is important to reach the diagnosis, clinical follow up is recommended in such lesion because there is a chance for recurrences

Patient consent:

Written consent and permission was taken from the patient to use his clinical, radiographic and histopathology diagnostic data for publication

References :

- [1] Dayisoğlu EH, Pampu AA, Mungan S, Taskesen F: Intramandibular canalicular adenoma: report of a rare case. *J Pak Med Assoc* 2012; 62: 1239-41.
- [2] Thompson LD, Bauer JL, Chiosea S, McHugh JB, Seethala RR, Miettinen M et al: Canalicular adenoma: a clinicopathologic and immunohistochemical analysis of 67 cases with a review of the literature. *Head Neck Pathol* 2015; 9:181-95.
- [3] Samar ME, Avila RE, Fonseca IB, Anderson W, Fonseca GM, Cantín M.: Multifocal canalicular adenoma of the minor labial salivary glands. *Int J Clin Exp Pathol* 2014; 7: 8205-10.
- [4] Ortega RM, Bufalino A, Almeida LY, Navarro CM, Travassos DC, Ferrisse TM et al: Synchronous Polymorphous Adenocarcinoma and Canalicular Adenoma on the Upper Lip: An Unusual Presentation and Immunohistochemical Analysis. *Head Neck Pathol* 2018;12(1):145-49.
- [5] Oliveira-Santos C, Freitas-Faria P, Damante JH, Consolaro A: Asymptomatic nodules of the upper lip: report of a canalicular adenoma with immunoprofile presentation. *Gerodontology* 2012; 29(2): e1121-24.
- [6] Sivolella S, Valente M, De Biagi M, Mazzoleni S, Stellini E: Canalicular adenoma immunoprofile: a case report. *Gerodontology* 2014; 31: 320-24.
- [7] Ahren C, Lindstrom J. Adenomatosis of accessory salivary glands of the lip. Report of two cases. *ORL J Otorhinolaryngol Relat Spec.* 1977;39:161-6.
- [8] Grimm EE, Rulyak SJ, Sekijima JH, et al. Canalicular adenoma arising in the esophagus. *Arch Pathol LabMed.* 2007;131:1595-7.
- [9] Huebner TA, Almubarak H, Drachenberg CB, et al. Canalicular adenoma-search for the cell of origin: ultrastructural and immunohistochemical analysis of 7 cases and review of the literature. *Ultrastruct Pathol.* 2014;38:74-82.
- [10] Jones AV, Craig GT, Speight PM, et al. The range and demographics of salivary gland tumours diagnosed in a UK population. *Oral Oncol.* 2008;44:407-17.
- [11] Seifert G, Sobin LH, editors. Histological typing of salivary gland tumours. In: WHO international histological classification of tumours. 2nd ed. Berlin: Springer; 1991
- [12] Lester D. R. Thompson et al. Canalicular Adenoma: A Clinicopathologic and Immunohistochemical Analysis of 67 Cases with a Review of the Literature. *Head and Neck Pathol.*2015; 9:181-195
- [13] Peraza AJ, Wright J, Gómez R. Canalicular adenoma: a systematic review. *J Craniomaxillofac Surg.* 2017;45:1754-8.
- [14] 14.Khullar SM, Best PV. Adenomatosis of minor salivary glands. Report of a case. *Oral Surg Oral Med Oral Pathol.* 1992;74:783-7.
- [15] Rousseau A, Mock D, Dover DG, et al. Multiple canalicular adenomas: a case report and review of the literature. *Oral Surg Oral Med Oral Pathol Oral Radiol Endod.* 1999;87:346-50.



Open Access This article is licensed under a Creative Commons Attribution 4.0 International License, which permits use, sharing, adaptation, distribution and reproduction in any medium or format, as long as you give appropriate credit to the original author(s) and the source, provide a link to the Creative Commons license, and indicate if changes were made. The images or other third-party material in this article are included in the article's Creative Commons license, unless indicated otherwise in a credit line to the material. If material is not included in the article's Creative Commons license and your intended use is not permitted by statutory regulation or exceeds the permitted use, you will need to obtain permission directly from the copyright holder. To view a copy of this license, visit <https://creativecommons.org/licenses/by/4.0/>.